


Republic of the Philippines
Department of Education
Region VII, Central Visayas
DIVISION OF CEBU PROVINCE
Sudlon, Lahug, Cebu City



August 13, 2019

DIVISION MEMORANDUM

No. 482 s, 2018

**REQUEST FOR VOLUNTARY FINANCIAL ASSISTANCE FOR MRS. MOONYEAN G.
BANGCORE**

To: Assistant Schools Division Superintendent
CID and SGOD Chiefs
CID and SGOD Personnel
Public Schools District Supervisors
Public Elementary and Secondary School Heads
All Teaching and Non-Teaching Personnel

1. Attached is a letter from Mr. Irenita Q. Navarro, Principal II, Vito Elementary School, requesting for voluntary financial assistance for Mrs. Moonyean G. Bangcore, Teacher , to defray expenses for her cancer treatment, details of which is stated in the attachment.
2. Relative to the above-mentioned circumstance, any voluntary financial contribution for this purpose shall be remitted to Mrs. Marites Peralta, Division Cashier who will turn over the money to the victim through her School Head.
3. Immediate dissemination of this Memorandum is desired.


RHEA MAR A. ANGTUD, Ed. D.
Schools Division Superintendent 



Department of Education
Region VII Central Visayas
Division of Cebu
Minglanilla I District
VITO ELEMENTARY SCHOOL



July 22, 2019

RHEA MAR A. ANGTUD, Ed. D., CESO VI
Schools Division Superintendent
Cebu Province Division

Ma'am:

Salutations!


As principal of Vito Elementary School, Minglanilla I District, I am deeply distraught by the condition of one of my dedicated teachers – **MRS. MOONYEAN G. BANGCORE**. She is currently at a certain stage of her cancer treatment that may last for three months – reason that she is on sick leave needless to say. I and all the faculty members have seen her financial struggles due to the series of medications she is undergoing; she even refuses to be absent to make ends meet. It is heartbreaking seeing her fighting both for life and meeting the finances needed in the process.

On this note, I would like to request your good office the assistance to ask financial support for our dear Mrs. Bangcore from the schools in our division. This is the least we can do for her and we hope to make miracles through this effort along with prayers.


Attached here are her medical documents.

We hope this humble request merits your kindest support.

Sincerely yours,


IRENITA Q. NAVARRO
School Principal 2

Noted:


JOEL B. UMBAY
Public Schools District Supervisor

Approved:


RHEA MAR A. ANGTUD, Ed. D., CESO VI
Schools Division Superintendent
Cebu Province Division



Department of Education
Region VII Central Visayas
Division of Cebu
Minglanilla I District
VITO ELEMENTARY SCHOOL



July 22, 2019

RHEA MAR A. ANGTUD, Ed. D., CESO VI
Schools Division Superintendent
Cebu Province Division

Ma'am:

Salutations!


As principal of Vito Elementary School, Minglanilla I District, I am deeply distraught by the condition of one of my dedicated teachers – **MRS. MOONYEAN G. BANGCORE**. She is currently at a certain stage of her cancer treatment that may last for three months – reason that she is on sick leave needless to say. I and all the faculty members have seen her financial struggles due to the series of medications she is undergoing; she even refuses to be absent to make ends meet. It is heartbreaking seeing her fighting both for life and meeting the finances needed in the process.


On this note, I would like to request your good office the assistance to ask financial support for our dear Mrs. Bangcore from the schools in our division. This is the least we can do for her and we hope to make miracles through this effort along with prayers.

Attached here are her medical documents.

We hope this humble request merits your kindest support.

Sincerely yours,


IRENITA Q. NAVARRO
School Principal 2

Noted: 
JOEL B. UMBAY
Public Schools District Supervisor

Approved:


RHEA MAR A. ANGTUD, Ed. D., CESO VI
Schools Division Superintendent
Cebu Province Division

CEBU DOCTORS' UNIVERSITY HOSPITAL
Osmeña Boulevard, Cebu City 6000

DEPARTMENT OF LABORATORY MEDICINE

**HISTOPATHOLOGY SECTION
SURGICAL PATHOLOGY / CYTOLOGY REPORT**

NAME	: GEONZON, MOONYEAN RODRIGU	HOSP. NO.	: 78942	Histopath #	: 07S - 5245
AGE	: 38	ADM.NO.	: 200212	Test Requested	:
SEX	: Female	C.S. #	: C1021487L	Sample Submitted	: 11/06/2007
ROOM #	: 310			Date Reported	: 11/6/2007 4:26:07PM
WARD	: 3A			Date Charged	: 10/26/2007 1:06:16PM
PHYSICIAN	: DR. MANUEL JR. VILLAMOR				

Specimen:

MRM, RIGHT S/P EXCISION BIOPSY (Ref # 07s - 4991)

GROSS EXAMINATION:

Received is the right breast with attached axillary tail totally weighing 1000 grams and measuring 195 x 200 x 40 mm. It is partially covered by an ellipse of skin measuring 180 x 60 x 2 mm with the nipple and areola complex located 80 mm from the medial end. Slight nipple retraction is noted. There is no skin ulceration seen. A healed incision measuring 20 mm long is noted below the nipple. An ill-defined, soft to firm, light tan to pink, stellate mass measuring 40 x 40 x 30 mm is noted beneath the healed incision.

The axillary tail measures 70 x 55 x 20 mm. Ten lymph nodes are recovered with sizes ranging from 3 to 15 mm in diameter.

Representative sections are processed as A - mass. B - nipple. C - superior margin, D - inferior margin. E - medial margin, F - lateral margin. G - posterior margin. H - lymph nodes.


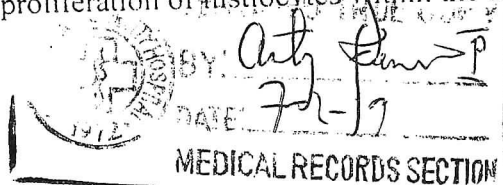
MICROSCOPIC EXAMINATION:

Microscopic examination of slides labelled A show sections of breast tissue involved in malignant neoplasm. The latter consists of anaplastic cells with pleomorphic vesicular nuclei, conspicuous nucleoli and moderate eosinophilic cytoplasm. The tumor cells fill dilated ducts and form solid nests and cords that are surrounded by lakes of mucin as they invade the surrounding stroma. Mitotic figures are rare. The adjacent areas show variably-sized ducts lined by a bilayer of cuboidal cells and exhibiting mild epithelial proliferation.

Slide labelled B shows sections of nipple tissue exhibiting tumor cells invading the stroma at the level of the lactiferous ducts. The overlying epithelium is unremarkable.

Slides labelled C, D, E, F and G show sections of fibrofatty tissues exhibiting congestion. There are no tumor cells seen.

Slides labelled H show sections of ten lymph nodes, none of which exhibit tumor involvement. These show benign proliferation of histiocytes within the sinuses.



CEBU DOCTORS' UNIVERSITY HOSPITAL
Osmeña Boulevard, Cebu City 6000



DEPARTMENT OF LABORATORY MEDICINE

**HISTOPATHOLOGY SECTION
SURGICAL PATHOLOGY / CYTOLOGY REPORT**

NAME	: GEONZON, MOONYEAN RODRIGU	HOSP. NO.	: 78942	Histopath #	: 07S - 5245
AGE	: 38	ADM.NO.	: 200212	Test Requested	:
SEX	: Female	C.S. #	: C1021487L	Sample Submitted	: 11/06/2007
ROOM #	: 310			Date Reported	: 11/6/2007 4:26:07PM
WARD	: 3A			Date Charged	: 10/26/2007 1:06:16PM
PHYSICIAN	: DR. MANUEL JR. VILLAMOR				


DIAGNOSIS:
MRM, Right S/P Excision Biopsy (Ref # 07s - 4991) : INVASIVE DUCTAL CARCINOMA, MUCINOUS TYPE, NUCLEAR GRADE 1, HISTOLOGIC GRADE 1, (pT2 N0 Mx); POSITIVE TUMOR INVOLVEMENT IN THE DEEPER PORTIONS OF THE NIPPLE; MARGINS OF EXCISION NEGATIVE FOR TUMOR INVOLVEMENT; SINUS HISTIOCYTOSIS IN TEN LYMPH NODE EXAMINED

COMMENTS:



Encoder: AIRES N. MADLANGBAYAN
Resident: _____
Date Printed: 11/7/2007 1:05:45PM
Page 2 of 2

[Signature]
ALMA E MALILONG, M.D.
PATHOLOGIST
LIC #: 0045935
PTR #: 176844



HI-PRECISION
diagnostics

LABCORE INC.

Name : BANGCORE, MOONYEAN GEONZON
PID : CT1428829
Age : 50Y Sex : FEMALE
Clinician: DR. MANUEL S. LEGASPI

Lab. Number : 1951152710
Source : HPD1 (WALK-IN)
Dispatch :
Page : 1 of 1

Date Received: 05-28-19 11:18

Reported: 05-29-19 09:57

Printed: 05-29-19 12:19

Date Received: 05-28-19 11:10					
TEST	RESULT	UNIT	REFERENCE RANGES		
HEMATOLOGY					
Blood Typing (ABO & Rh)					
ABO Typing	B				
RH Typing	POSITIVE				
Conventional Units			SI Units		
CHEMISTRY					
SGPT/ALT	13	U/L	< 34	13.00	U/L
Alkaline Phosphatase	89	U/L	20 ~ 130	89.00	U/L
IMMUNOLOGY					
CA 15-3 (Breast CA)	H 133.90	U/ml	< 25.00		
* TEST DONE TWICE.					

CH:
ALLEN EARL S. LEDESMA, RMT
LIC # 0061270

SI:
JOYCE KIM Z. NUEVO, RMT
LIC # 0073542

HM:
RADNER P. GRANADA, RMT
LIC # 0056491

GRACE JOY D. AVILA, M.D., I
PTR 1680572, LIC# 0091151, CTC 12X

MEDICAL TECHNOLOGISTS

** Report Electronically Signed Out **

PATHOLOGIST

BRANCHES



PERPETUAL SUCCOUR

Gorordo /
Tel. No. 233-

MEDICAL IMAGING

Patient Name **BANGCORE, MOONYEAN GEONZO**
Hosp. No. **519413**
Ref. Physician **MARTINIANO ZANORIA**
Exam Taken **CHEST (CONTRAST) (GE)**
Address **CEBU CITY, CEBU**

INTERPHASE

CHEST (CONTRAST)

*History: Diagnosed case of thymoma (1999) and breast CA
In the interim, had yearly chest x-rays outside and g
few months prior to scan, noted lymph nodes in the
Advised CT scan for further work-up*

Plain and intravenous contrast-enhanced axial C.T. images

The right breast is surgically absent. There is an ovoid hom
wall abutting the right 4th costal cartilage measuring approx

There is nodular thickening and enhancement of both anter
of both hilar structures and anterior upper lobes anteriorly.
compressed. The azygous veins are prominent with collater

Multiple varisized spiculated parenchymal and fissural/pleu
and lower lobes, the largest in the posterior right upper lobe

Minimal fluid collection is noted in the right pleural space.

The mediastinal compartments are intact with no masses d

Enlarged prevascular, paratracheal, subcarinal and both hil
inferior paratracheal region measures 2.4 x 3.0cm.

Enlarged bilateral supraclavicular and axillary lymph nodes
the right axillary region.

The great vessels are normal in course and caliber with no

IRMA ALICIAS-VEROY, MD, FPCR, FUSP

Fellow, CT-MRI Society
Gorordo Avenue, Cebu City

PERPETUAL SUCCOUR HOSPITAL OF CEBU, INC.

PITAL OF CEBU, INC.

Cebu City
122 or 123

ENTER

Age 50 Adm. No. 1216684B
Sex FEMALE File No. CT19-1816
Room No. OPD

Exam Date: 5/18/2019

ION

*S/P radiation and chemotherapy;
w-up check ups with her doctor;
vicular region on palpation.*

chest reveal the following findings:

isly enhancing mass in the right anterior chest
4.0 x 1.3 x 3.8cm.

or pleura and anterior mediastinum with traction
al segments of the superior vena cava is
als in the paravertebral region.

les and mass are scattered in both upper, middle
res 3.3 x 3.6cm.

ated.

n nodes are seen, the largest in the anterior

wise seen, the largest measures 4.4 x 2.3cm in

ie of aneurysm nor dissection.

MA. LUISA S. ANATAN, MD, FPCR, FUSP

MRL Society

PERPETUAL





PERPETUAL SUCCOUR HOSPITAL OF CEBU, INC.

Gorordo Avenue, Cebu City
Tel. No. 233-8620 loc. 122 or 123

MEDICAL IMAGING CENTER

Patient Name	BANGCORE, MOONYEAN GEONZON	Age	50	Adm. No.	1216684B
Hosp. No.	519413	Sex	FEMALE	File No.	CT19-1816
Ref. Physician	MARTINIANO ZANORIA			Room No.	OPD
Exam Taken	CHEST (CONTRAST) (GE)				
Address	CEBU CITY, CEBU				

Exam Date: 5/18/2019

INTERPRETATION

The heart is likewise normal in size and configuration.

Minimal fluid is noted in the pericardial space measuring 1.5cm in maximal thickness along the inferior border of the left ventricle.

The osseous structures and chest musculature are unremarkable.

Incidentally, calcified lithiasis are seen in the visualized gallbladder. Multiple enlarged retrocrural, paraaortic and retrocaval lymph nodes are seen, the largest in the retrocaval region measures 3.9 x 2.2cm.


IMPRESSION:

- 1) Heterogeneously enhancing mass in the right anterior chest wall at the level of the right 4th costal cartilage consistent with tumor recurrence (Diagnosed case of breast CA, S/P mastectomy).
- 2) Parenchymal pleural and fissural nodules and mass consistent with metastases.
- 3) Nodular, anterior pleural and anterior mediastinal thickening and enhancement with cicatrization compressing the superior vena cava likely post radiation changes.
- 4) Right pleural effusion.
- 5) Mediastinal, supraclavicular, axillary, retrocrural, paraaortic and retrocaval lymphadenopathies consistent with metastases.
- 6) Minimal pericardial effusion.
- 7) Incidental findings of cholelithiasis.

IRMA ALICIAS-VEROY, MD, FPCR, FUSP
Fellow, CT-MRI Society

MA. LUISA SUGATAN-TAN, MD, FPCR, FUSP
Fellow, CT-MRI Society

572111



REPUBLIC OF THE PHILIPPINES
DEPARTMENT OF HEALTH

VICENTE SOTTO MEMORIAL MEDICAL CENTER
B. Rodriguez Street, Cebu City 6000
ONCOLOGY DEPARTMENT

MEDICAL ABSTRACT

NAME : *Bangane, Wenguan* HOSPITAL NO.:
WARD & BED NO. : AGE: *50* SEX: *F* CS: *W*
ADDRESS : *Kingfailla, Cebu*
DATE ADMITTED : *6/6/19*
DIAGNOSIS : *breast cancer*

BRIEF HISTORY :

*pt was operated for breast cancer & was
referred for chemotherapy*

LABORATORY WORK-UP:

histopath revealed inv. ductal CA

PRESENT MEDICATION:


none


PLAN:

*to cytotoxic chemotherapy with doxorubicin,
cyclophosphamide & irinotecan*

REASON FOR REFERRAL:

Primary


MANUEL S. LEGASPI III
LICENSE NO.: 52108
PTR EXEMPTED: GOV'T MD
MEDICAL ONCOLOGY SPECIALIST




Vicente Sotto Memorial Medical Center
Section of Medical Oncology

TREATMENT PROTOCOL

Name of Patient: Francisco, Wanylen Diagnosis: breast cancer

MEDICINES	PREPARATION	PATIENT'S ACTUAL DOSE	# OF VIALS PER CYCLE	TOTAL NUMBER OF VIALS FOR THE ENTIRE TREATMENT
① Doxorubicin	2mg / ml very / ml	7 mg	1 2	6 12
② Cyclophosphamide	very / ml	45mg	1	6


LAWRENCE S. LERNER, MD
Internal Medicine
License: Specialist
License No. 58108
PTR No: (Exempted Gov. MD)



VICENTE SOTTO MEMORIAL MEDICAL CENTER
B. Rodriguez St., Cebu City

PRESCRIPTION

Full Name: Kamcar, Maryann FUNDING
Ward / Unit: _____ Age & Sex: DD / F Date: 6/6/19
Tag #: _____ Charge #: _____ I.D. #: _____

Rx

① Intracanal syal ^{MSW / PHIC / BILLING}
syal #2

S 12mg IV inveni

② carbamate 4mg in the

S 4mg IV in the

MANUEL S. LEONARDO, MD M.D.
Internal Medicine
Cancer Specialist
[doctor's tru-dat bears name, license # & S2 license #)
License No. 52108
PM noted

Issued By: _____

Minutes Rx

Received By: _____

recvd. to filled: _____



VICENTE SOTTO MEMORIAL MEDICAL CENTER
B. Rodriguez St., Cebu City

PRESCRIPTION

Full Name: Pangane Monique **FUNDING**
Ward / Unit: _____ Age & Sex: _____ Date: 6/27/18
Tag #: _____ Charge #: _____

Rx

For the IT was cancerous.
This is to certify that I
am currently treating her.
Monique Pangane of
recent breast cancer.
She is scheduled to go in
and have drug her cancer
of chemotherapy every 6 hrs (4)
wks.

WILSON S. LERASPI, MD M.D.
Internal Medicine
[Doctor's stamp below Signature # & S2 license #)
License No 52108

Issued By: M. Lerassi

Received By: _____